

Anatomy : is the field in the biological sciences concerned with the identification and description of the body structures of living things.

Divided into :

- Gross anatomy :

customarily refers to the study of those body structures large enough to be examined without the help of magnifying devices.

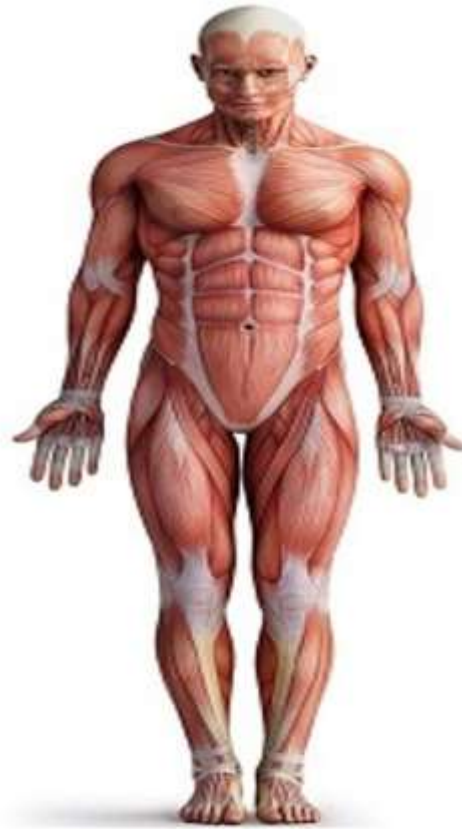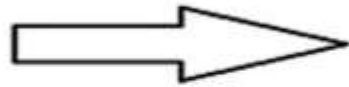
- Microscopic anatomy :

concerned with the study of structural units small enough to be seen only with a light microscope , electron microscope.

Anatomical Position :

Anatomical position, or standard anatomical position, refers to the specific body orientation used when describing an individual's anatomy. Standard anatomical position of the human body consists of the body standing upright and facing forward with the legs parallel to one another. The upper limbs, or arms, hang at either side and the palms face forward.

The Anatomical Position



ad&co/shutterstock.com

★ If the body is lying flat instead of standing upright, with the same positioning of the limbs, it is known as the **supine position**.

Anatomical plane :

An **anatomical plane** is a hypothetical plane used to transect the body, in order to describe the location of structures or the direction of movements in human anatomy.

three principal planes are used:

Coronal plane.

Sagittal plane.

Axial plane.

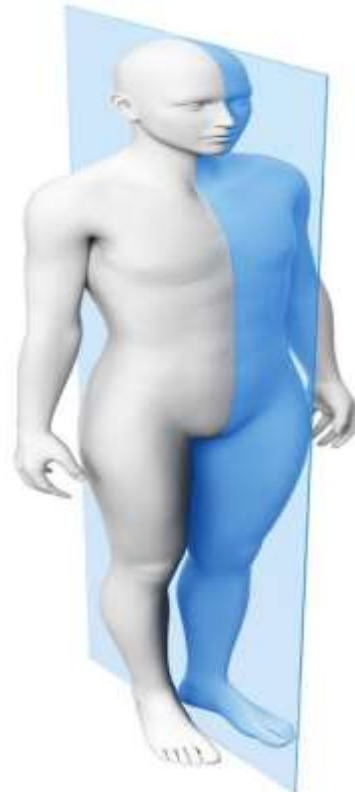1- Coronal plane :

The coronal plane or frontal plane divides the body into dorsal and ventral (back and front, or posterior and anterior) portions.



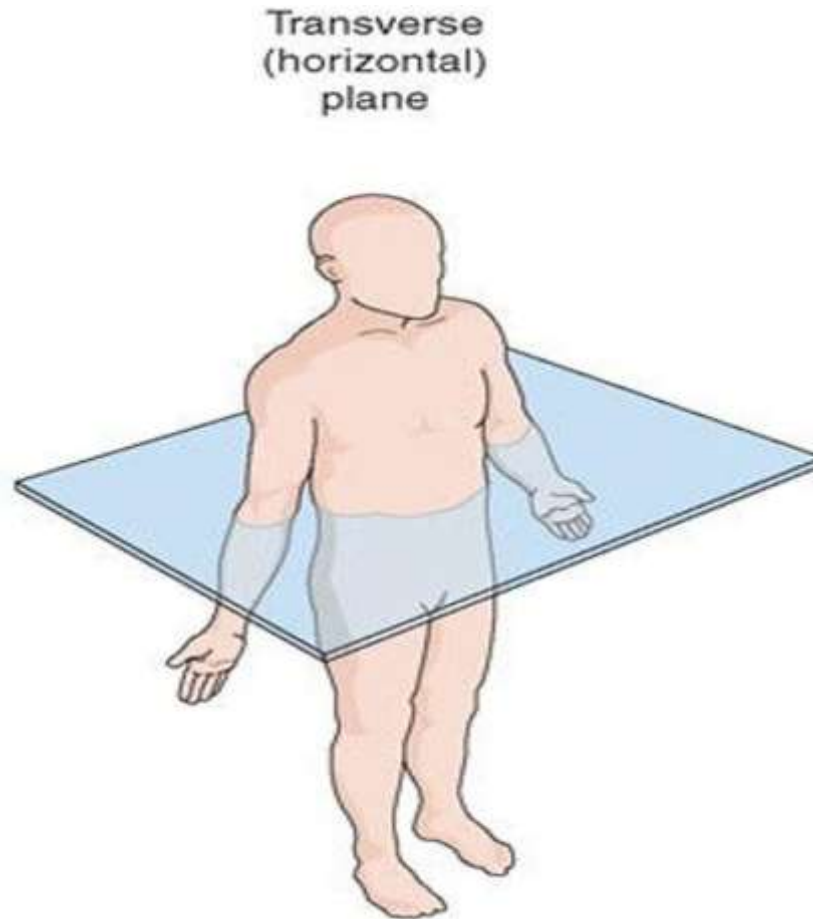
2- Sagittal plane :

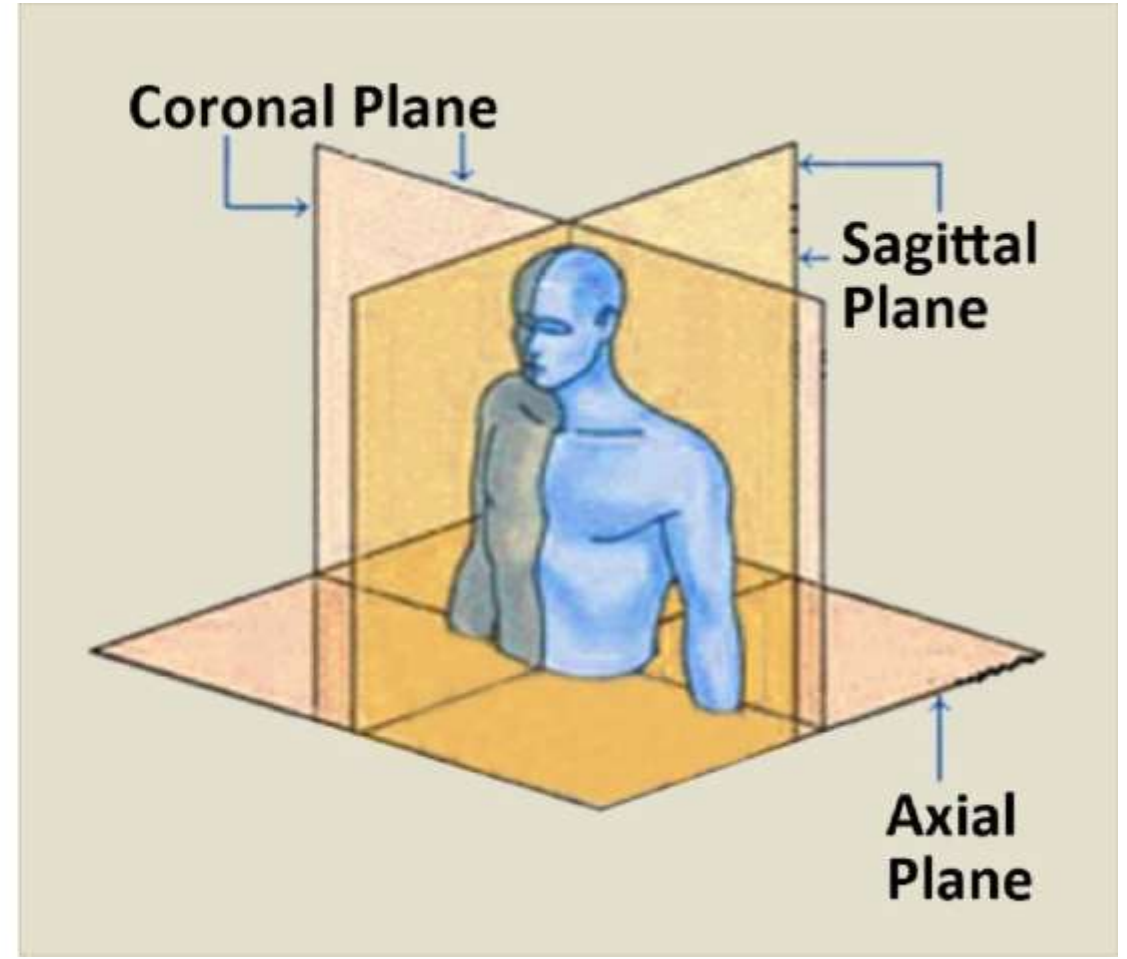
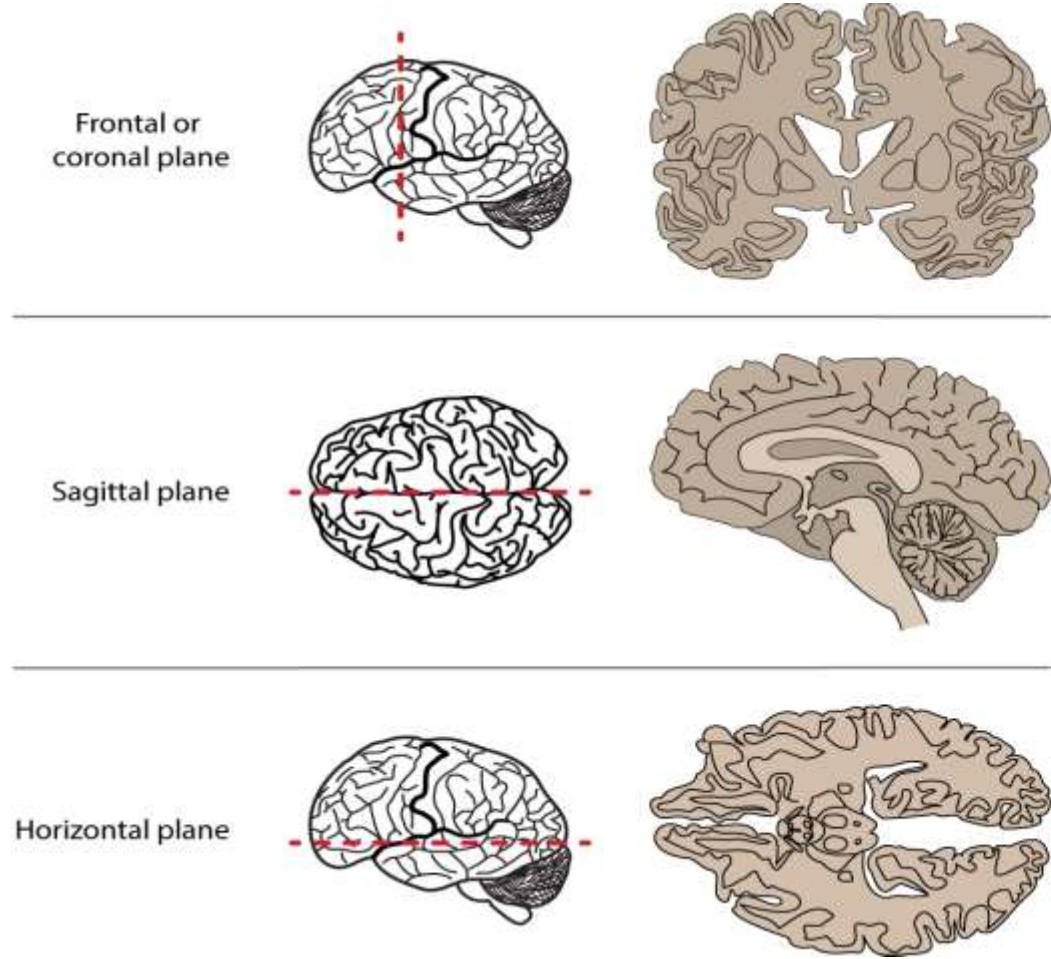
The sagittal plane or lateral plane (*longitudinal, anteroposterior*) is a plane parallel to the sagittal suture. It divides the body into left and right.



3- Axial plane:

The transverse plane or axial plane (*horizontal*) divides the body into cranial and caudal (head and tail) portions.





Anatomical Directions:

It usually **Anterior:** Anterior means "in front of" or "the front surface of" refers to the front side of the body. **For example, your knee caps are on the anterior part of your body.**

Posterior: Posterior in anatomy pertains to the back of the body. When describing a body part, it is either located posteriorly or anteriorly. If one is standing in the anatomical position, posterior refers to the back side, so the location of the body part is based on this **For example , your vertebral column is on the posterior part of your body.**

Superior :

or cranial - toward the head end of the body; upper (example, the hand is part of the superior extremity).

Inferior :

or caudal - away from the head; lower (example, the foot is part of the inferior extremity).

Superficial : a concept that denotes superficiality or surface, in other words, whenever the intended organ or part is close to the skin, the more superficial it is. For example Superficial fascia In contrast to the Deep fascia.

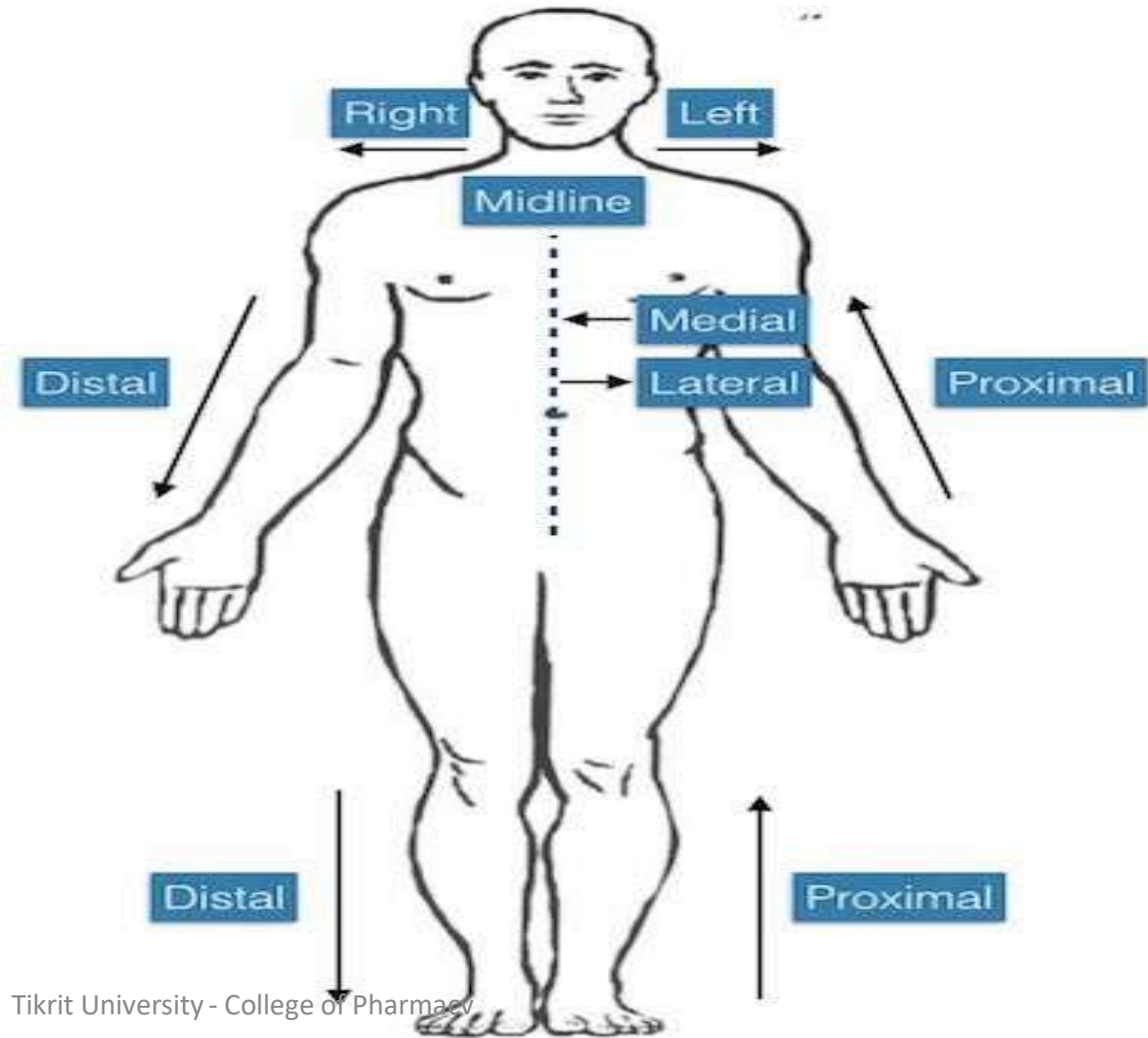
Median : Sagittal plane through the midline of the body; divides the body or any of its parts into right and left halves. For example **The trachea is a median structure.**

Medial : toward the midline of the body (example, **the middle toe is located at the medial side of the foot).**

Lateral: away from the midline of the body (example, **the little toe is located at the lateral side of the foot).**

Proximal : toward or nearest the trunk or the point of origin of a part and refers to a part of the body that is closer to the center of the body than another part. For example (**the shoulder is a proximal part of the arm).**

Distal: away from or farthest from the trunk or the point or origin of a part . For example (the hand is located at the distal end of the forearm).





**THANK
YOU!**